



Greetings

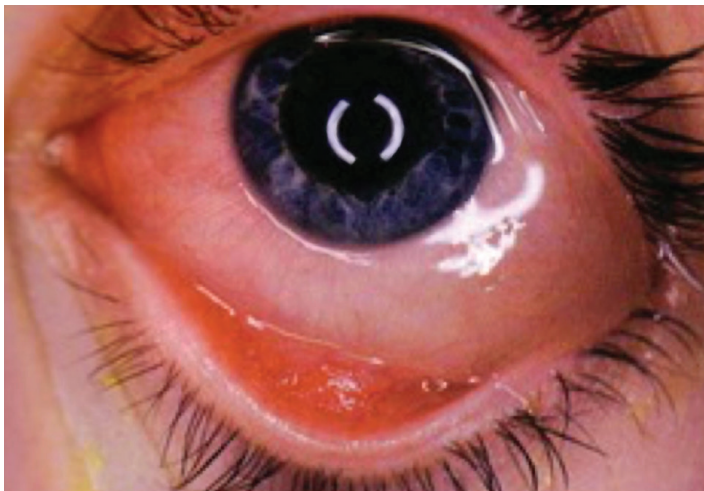
Dear Colleagues:

Welcome to the spring edition of *Pediatric Eye News*. As the weather gets warmer and the flowers begin to bloom, we see an influx of patients suffering from seasonal allergies. Therefore, it seems only fitting that this edition focuses on allergic ocular disease, a common and bothersome condition. Our goal is to provide you with a concise overview of allergic conjunctivitis to aid in the primary treatment of your pediatric patients. As always, this newsletter provides a brief review of the latest journal literature and an "EyeQ Test" to challenge your ophthalmic knowledge. Electronic copies of the newsletter and detailed information about our outstanding physicians, services, and facilities can be found on our webpage at <http://childrensnyp.org/mschony/ophthalmology.html>.

Division News

The Division continues to welcome referrals and new patients at its two Manhattan locations: the Stephen M. Ross Center for Pediatric Ophthalmology, located on the fifth floor of the Morgan Stanley Children's Hospital of New York, and the Robert Burch Family Eye Center, located on the first floor of the Lighthouse Guild building at Lincoln Center.

This past month, we held our first subspecialty clinic devoted to the treatment of infants and children with pediatric cataract or glaucoma. Co-directed by Steven Kane, M.D., Ph.D., Associate Clinical Professor of Ophthalmology and Steven Brooks, M.D., Anne S. Cohen Professor of Pediatric Ophthalmology, the clinic offers complete medical and surgical care for patients with these rare and complicated conditions. It is held on the second Friday of every month at the Edward S. Harkness Eye Institute.



Ocular Allergies

Allergic ocular disease is a common clinical entity in children that is often associated with asthma, allergic rhinitis, and atopic dermatitis. **Seasonal allergic conjunctivitis** occurs in the spring and fall, and can be triggered by certain environmental allergens such as pollen. These allergens cause a Type I hypersensitivity reaction with IgE antibodies on the surface of mast cells in the conjunctiva. Patients typically complain of red, watering, and itching eyes, and may have slightly edematous, or boggy, conjunctiva (see photo). Frequently, patients may develop "allergic shiners," which are purple or blue-grey discolorations of the lower eyelids due to venous stasis from nasal congestion.

Perennial conjunctivitis may present in a similar fashion. However, this condition is not related to seasonal allergens, and instead is a response to household allergens, such as dust mites or pet dander. **Vernal keratoconjunctivitis (VKC)** is a specific type of ocular allergy that occurs seasonally and affects young boys and teenagers. These patients present with severe itching in both eyes, and often exhibit a more severe ocular response, such as the development of corneal nodules or sterile corneal ulcers. Typically, patients with VKC are less responsive to topical antihistamine and vasoconstrictor treatments than those with seasonal allergic conjunctivitis.

The treatment of ocular allergy is similar to that of other allergy-related disorders. The first step is to remove all offending allergens from the patient's environment. Medical treatments can be topical or systemic with the most commonly used topical medications being mast-cell stabilizers, H1-receptor blockers, vasoconstrictors, and mast-cell

(continued on page 2)

EyeQ Test:



1. True or False: Intermittent eye crossing is normal in children up to one-year of age.
2. Potential causes of bilateral congenital cataracts include all of the following except:
 - a. Leukemia
 - b. TORCH infections
 - c. Galactosemia
 - d. Idiopathy
3. Tearing with cloudy corneas in a newborn is a sign of:
 - a. Congenital cataracts
 - b. Congenital glaucoma
 - c. Neonatal conjunctivitis
 - d. Blocked nasolacrimal ducts
4. Symptoms of a corneal abrasion include all of the following except:
 - a. Photophobia
 - b. Eye pain
 - c. Tearing
 - d. Purulent discharge
5. True or False: Loss of extraocular movement is a feature of preseptal cellulitis.

Answers: 1. False, 2. a, 3. b, 4. d, 5. False

Ocular Allergies *(continued from page 1)*

stabilizer/H1-receptor blocker combination drops. Mast-cell stabilizers may take several days or weeks to work. Vasoconstrictors, on the other hand, work quickly to reduce edema, but are less effective at relieving itching and are only meant to be used for a few days. In more severe cases, topical steroids may also be prescribed for short-term use. It is important that children who are prescribed topical steroids also be monitored for side effects, such as cataracts, glaucoma, and corneal infections. Accordingly, treatment with topical steroids should only be conducted under the supervision of an ophthalmologist. Oral antihistamines are generally less effective than topical medications, but are a good option for children averse to eye drops, as well as those with concurrent non-ocular symptoms or atopy. Alternative diagnoses might be required for children who do not respond promptly to treatment, or who have eye pain, photophobia, unilateral disease, or changes in vision. In these cases, referral to a pediatric ophthalmologist should be considered.

Journal Round-Up

In a recent *JAMA Pediatrics* article, Bao Truong, M.D. and colleagues discussed significant disparities in patient care and outcomes for children with retinoblastoma. Their findings emerged from a review of 18 Surveillance, Epidemiology, and End Results (SEER) registries across the United States from January 2000 through December 2010. In 830 cases of children aged 0-9 years, the authors analyzed factors including race, ethnicity, poverty level, education, language isolation, crowding, unemployment, and percentage of immigrants in the community. They found that the extent of the disease at presentation and the likelihood of enucleation varied significantly among the socioeconomic groups. While 33% of Hispanic children presented with extraocular disease, only 20% of non-Hispanic white children did. Hispanic children were also 41% more likely to undergo enucleation compared with non-Hispanic white children. The authors concluded that identifying and addressing such disparities is critical given the morbidity, and long-term psychological, financial, and medical burdens, that these children and families endure. (Racial and Socioeconomic Disparities in Retinoblastoma. *JAMA Pediatrics* 2015; 169(12):1096-1104.)

pediatric eye news

*A Publication of the Department of Ophthalmology,
Division of Pediatric Ophthalmology, Columbia
University Medical Center and the Morgan Stanley
Children's Hospital of New York*

Pediatric Ophthalmologists:
Steven Brooks, M.D. (Division Chief)
Lauren Yeager, M.D.

Practice Locations:
Morgan Stanley Children's Hospital
3959 Broadway, New York, NY (5th floor)
15 west 65th St., New York, NY
(Lighthouse-Guild Building)

For Appointments Call: 212-305-9535